



Body Condition Scores in Goats

M. Villaquiran, T. A. Gipson, R. C. Merkel,
A. L. Goetsch, and T. Sahlu



Langston University
Agriculture Research & Cooperative Extension
Box 730
Langston, OK 73050

Ph. 405-466-3836
Fax 405-466-3138
<http://www2.luresext.edu>

Partially funded by USDA/CSREES Initiative for Future Agriculture and Food Systems project #0191130-OKLXGIPSON entitled "Enhanced Goat Production Systems for the Southern United States" and by USDA/FSIS/OPHS project #FSIS-C-10-2004 entitled "Development of a Web-based Training and Certification Program for Meat Goat Producers."

Body Condition Scores

Every goat producer has animals that are either too thin (under-conditioned) or too fat (over-conditioned). Failure to recognize these animals and take corrective actions will cost dearly in terms of decreased fertility, increased disease or internal parasite incidence, decreased milk production, and increased operating costs. Thus, goats need to be maintained with a moderate amount of body condition. When overall body condition starts to decrease in the herd, it is a sign that managerial intervention is needed such as supplemental feeding, deworming, pasture rotation, etc. Conversely, when overall body condition starts to increase in the herd, it is a sign that the producer should reduce supplemental feeding. Ignoring an animal's body condition and waiting to intervene until goats become either too thin or too fat may result in production and(or) animal losses or decreased profits from overfeeding. Therefore, producers need to develop skills in assessing body condition of their goats so that a desired moderate body condition can be maintained.

Body condition score (BCS) has been shown to be an important practical tool in assessing the body condition of cattle, sheep, and goats because BCS is the best simple indicator of available fat reserves which can be used by the animal in periods of high energy demand, stress, or suboptimal nutrition.

Scoring is performed in goats using a BCS ranging from 1.0 to 5.0, with 0.5 increments. In this publication, examples of BCS of 1.0, 2.0, 3.0, 4.0, and 5.0 are given using photographs and written descriptions. Assigning the 0.5 score increment is done when the animal being evaluated is intermediate to the BCS described in this publication. A BCS of 1.0 is an extremely thin goat with no fat reserves and a BCS of 5.0 is a very over-conditioned (obese) goat. In most cases, healthy goats should have a BCS of 2.5 to 4.0. BCS of 1.0, 1.5, or 2.0 indicate a management or health problem. A BCS of 4.5 or 5 is almost never observed in goats under normal management conditions; however, these BCS can sometimes be observed in show goats.

It is important to note that BCS cannot be assigned by simply looking at an animal. Instead, the animal must be touched and felt. The first body area to feel in determining BCS is the lumbar area, which is the area of the back behind the ribs containing the loin. Scoring in this area is based on determining the amount of muscle and fat over and around the vertebrae. Lumbar vertebrae have a vertical protrusion (spinous process) and two horizontal protrusions (transverse process). Both processes are used in determining BCS. You should run your hand over this area and try to grasp these processes with your fingertips and hand. The second body area to feel is the fat covering on the sternum (breastbone). Scoring in this area is based upon the amount of fat that can be pinched. A third area is the rib cage and fat cover on the ribs and intercostal (between ribs) spaces.

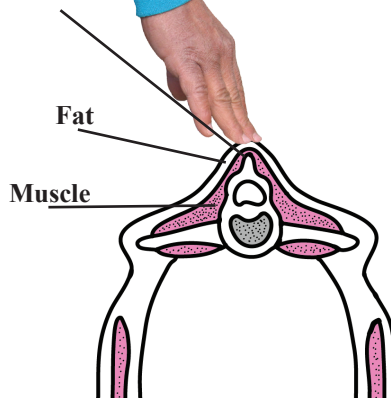
With practice, evaluating the BCS of an animal will only take about 10-15 seconds. By adding BCS as a regular part of your management program, you can more effectively monitor your feeding and herd health program for a healthy and productive herd.

“An Ounce of Prevention is Worth A Pound of Cure”

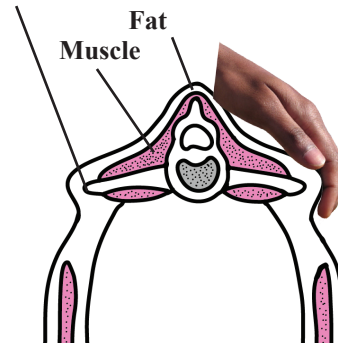
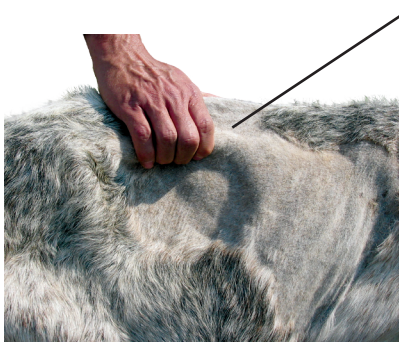The Cooperative Extension Program at Langston University provides educational programs to individuals regardless of race, color, national origin, religion, sex, age disability or status as a veteran. Issued in furtherance of Agricultural Extension Work Act of September 29, 1977, in cooperation with the U.S. Department of Agriculture.

Lumbar region

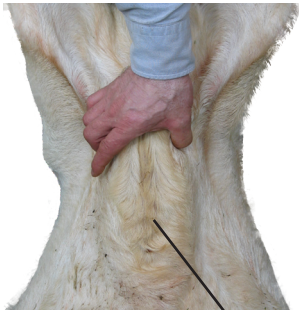Spinous process



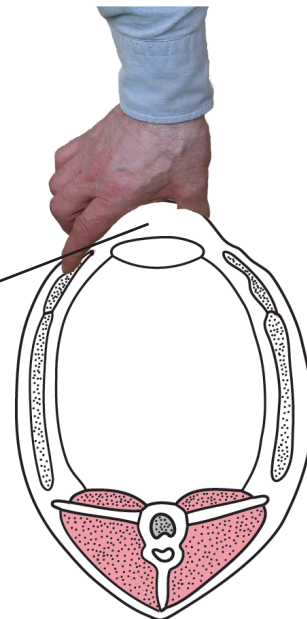
Transverse process



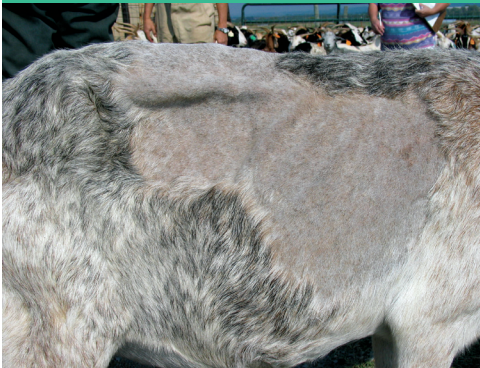Sternum



Fat



BCS 1.0



Visual aspect of the goat: Emaciated and weak animal, the backbone is highly visible and forms a continuous ridge. The flank is hollow. Ribs are clearly visible. There is no fat cover and fingers easily penetrate into intercostal spaces (between ribs).



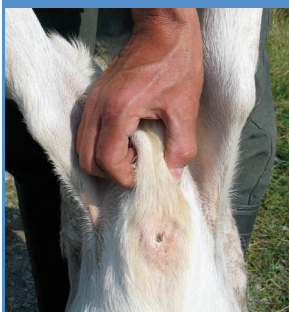The spinous process of the lumbar vertebrae can be grasped easily between the thumb and forefinger; the spinous process is rough, prominent, and distinct giving a saw-tooth appearance. Very little muscle and no fat can be felt between the skin and bone. There is a deep depression in the transition from the spinous to transverse process.



The hand can easily grasp the transverse process of the lumbar vertebrae which is very prominent. Clearly half of the length of the transverse process is discernible.

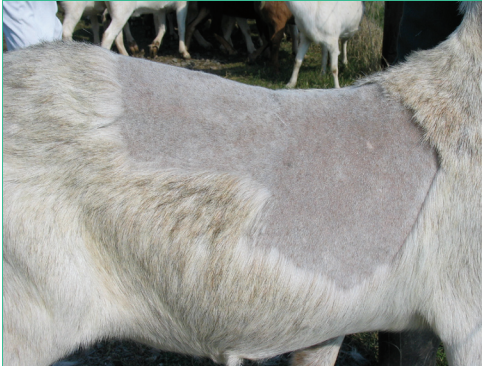

Diagrams adapted from Edmonson, et. al, 1989. J. Dairy Science, 72:68-78. Used with permission from the American Dairy Science Association.

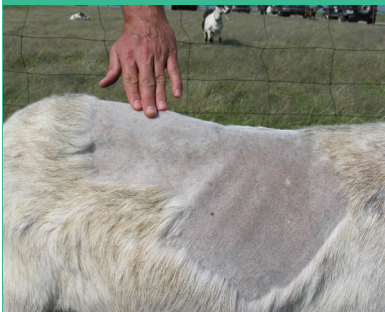

Sternal fat can be easily grasped between thumb and fingers and moved from side to side. The cartilage and joints joining ribs and sternum are easily felt.

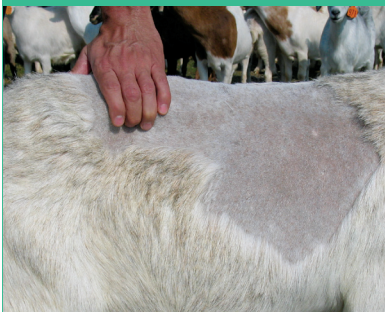BCS 2.0



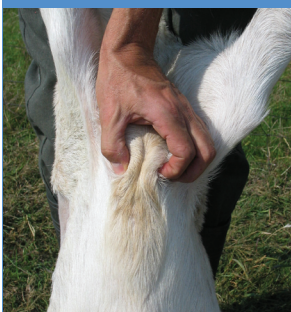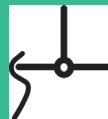Visual aspect of the goat: Slightly raw-boned, the backbone is still visible with a continuous ridge. Some ribs can be seen and there is a small amount of fat cover. Ribs are still felt. Intercostal spaces are smooth but can still be penetrated.



The spinous process of the lumbar vertebrae is evident and can still be grasped between the thumb and forefinger; however, a muscle mass can be felt between the skin and bone. There is an obvious depression in the transition from the spinous to transverse process.

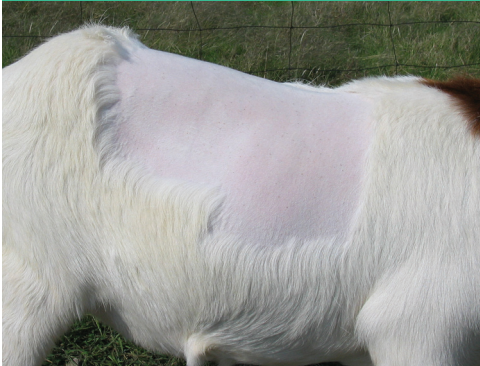

The hand can grasp the transverse process but the outline of the transverse process is difficult to see. About one-third to one-half of the length of the transverse process is discernible.

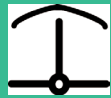
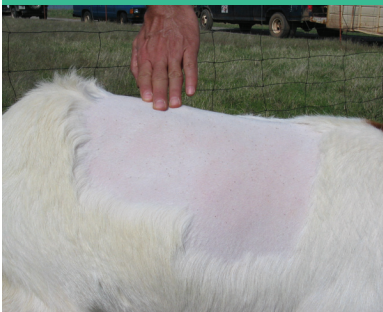
Sternal fat is wider and thicker but can still be grasped and lifted by the thumb and forefinger. The fat layer can still be moved slightly from side to side. Joints are less evident.

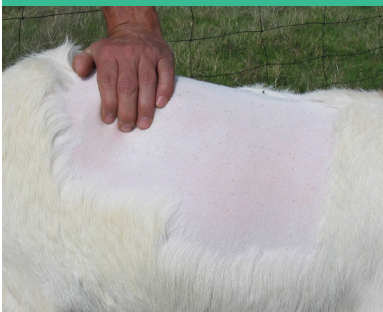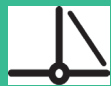BCS 3.0



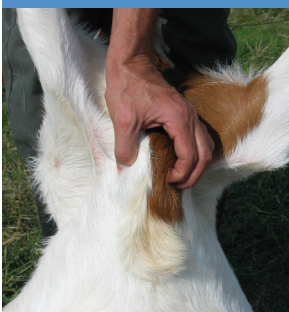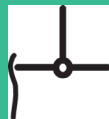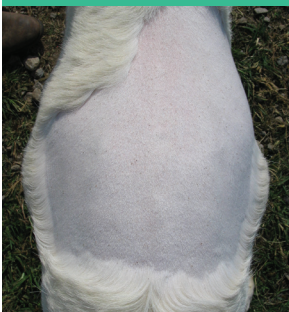Visual aspect of the goat: The backbone is not prominent. Ribs are barely discernible; an even layer of fat covers them. Intercostal spaces are felt using pressure.



The spinous process of the lumbar vertebrae cannot be easily grasped because the tissue layer covering the vertebrae is thick. When running a finger over the spinous process, a slight hollow is felt. There is a smooth slope in the transition from the spinous to transverse process.

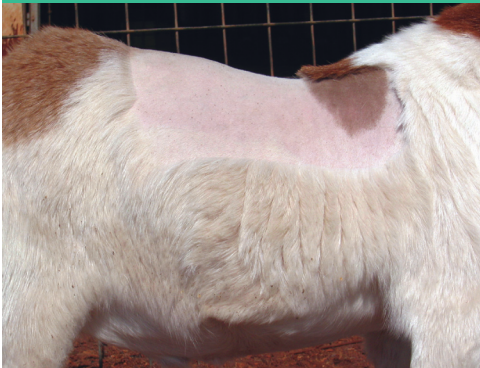

The outline of the transverse process of the lumbar vertebrae is slightly discernible. Less than one-quarter of the length of the transverse process is discernible.

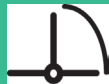
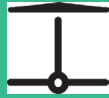
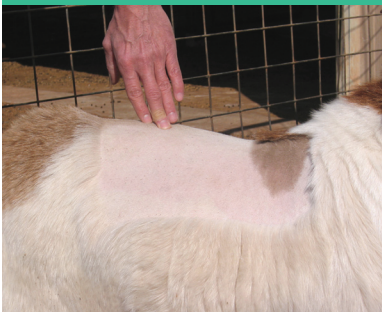Sternal fat is wide and thick. It can still be grasped but has very little movement. Joints joining cartilage and ribs are barely felt.

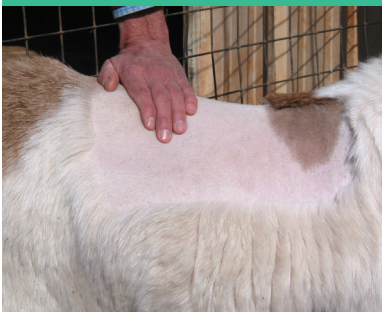BCS 4.0



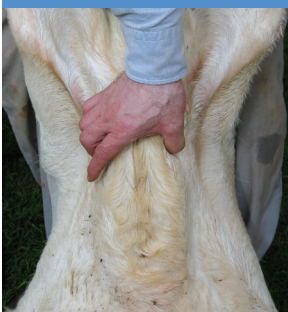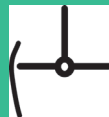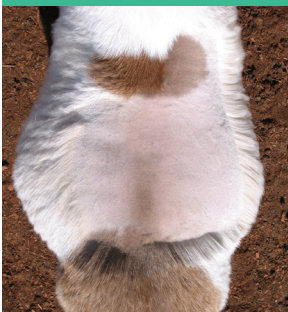Visual aspect of the goat: The backbone cannot be seen. Ribs are not seen. The side of the animal is sleek in appearance.



It is impossible to grasp the spinous process of the lumbar vertebrae, which is wrapped in a thick layer of muscle and fat. The spinous process forms a continuous line. There is a rounded transition from the spinous to transverse process.

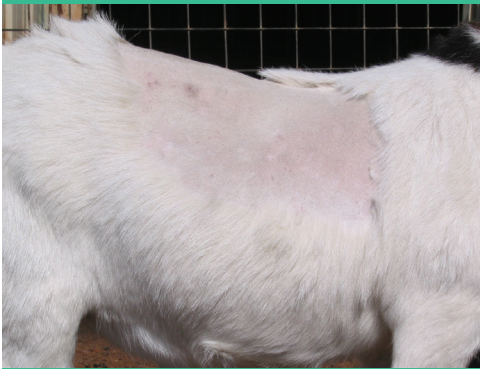

The outline of the transverse process of the lumbar vertebrae is no longer discernible. The transverse process forms a smooth, rounded edge, with no individual vertebrae discernible.

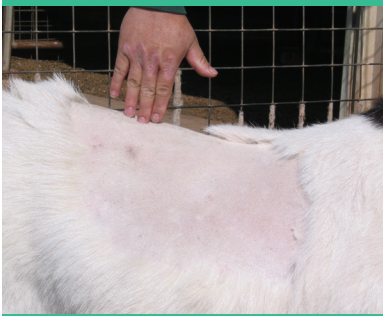

Sternal fat is difficult to grasp because of its width and depth. It cannot be moved from side to side.

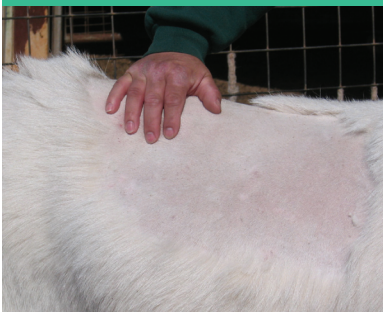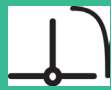BCS 5.0



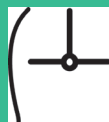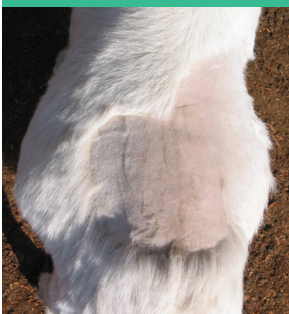Visual aspect of the goat: The backbone is buried in fat. Ribs are not visible. The rib cage is covered with excessive fat.



The thickness of the muscle and fat is so great that reference marks on the spinous process are lost. The spinous process forms a depression along the backbone and there is a bulging transition from the spinous to transverse process.



The thickness of the muscle and fat is so great that reference marks on the transverse process are also lost. It is impossible to grasp the transverse process.



The sternal fat now extends and covers the sternum, joining fat covering cartilage and ribs. It cannot be grasped.

