



Ultrasound for EMS
 It's not just for babies anymore!



Michael A. Kaufmann, MD, FACEP
 EMS Medical Director
 St. Vincent Health Services

Michael Kaufmann, MD, FACEP

- Vice President – St. Vincent Emergency Physicians, Inc.
- Board Certified EMS Physician
- EMS Medical Director
 - Boone County Sheriff's Office
 - Carmel Fire Department
 - Decatur Township Fire Department
 - Perry Township Fire Department Boone County
 - Pike Township Fire Department
 - Whitestown Fire Department
 - Zionsville Fire Department
 - Care Ambulance in Clay County
 - Midwest Ambulance Service
 - Seals Ambulance – Dunn, Bedford, Jennings
 - St. Vincent StatFlight
 - St. Vincent StatGround
 - St. Vincent EMS/Education



Objectives

- Describe the use of Ultrasound in the prehospital environment.
- Provide background information on proof of concept.
- Give real life examples of how ultrasound can help you and your patients.
- Give you some direction on how to get started.
- Tell you a little bit about our trauma program at St. Vincent Hospital.

Case Study

- It's Saturday night and your working Medic101 in a rural county of Indiana.
- You are called to the scene of a 45 y/o male who was shot in the back with a shot gun.
 - BP 100/50, HR 110, O2 Sats 90%
 - You are 20 minutes from the closest hospital
 - You place two large bore IV's and intubate
 - Just after intubation his vitals take a dump
 - BP 60/40, HR 160, O2 Sats 80% and dropping

Back GSW



What are you worried about?


- Pneumothorax
- Tension Pneumothorax
- Cardiac Tamponade
- Right mainstem intubation
- Esophageal Intubation
- Mis-placed endotracheal tube

Your first move should be?

- Check the tube
- Needle decompress the chest
- Pericardiocentesis
- Squeeze the bag harder
- More IV Fluids
- Diesel bolus (drive faster!)

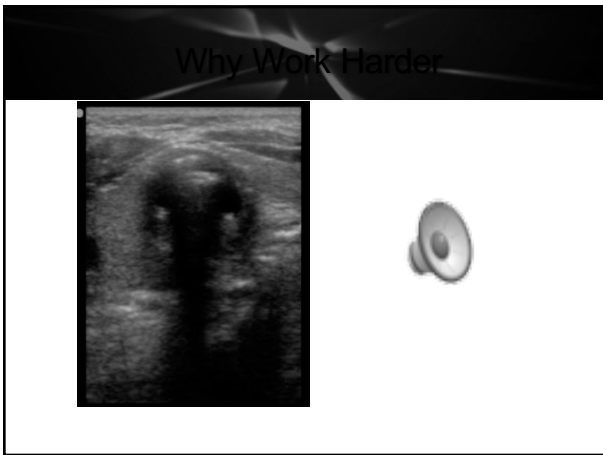
Let's Get to Work

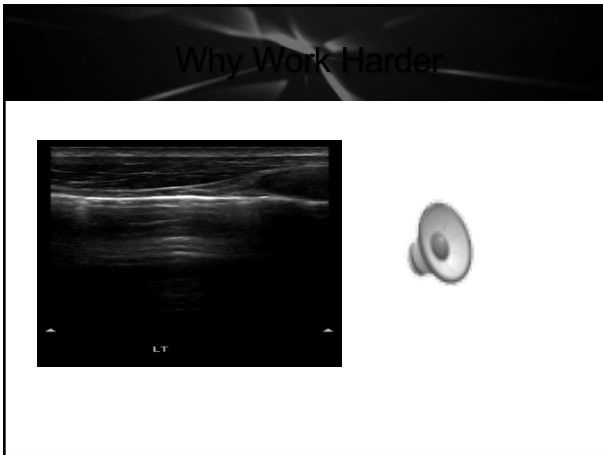
- How do we differentiate these bad things clinically?
 - Breath sounds ?
 - Blood pressure ?
 - JVD ?
 - Heart tones ?
 - Clinical Judgement ?
 - Ougie ?

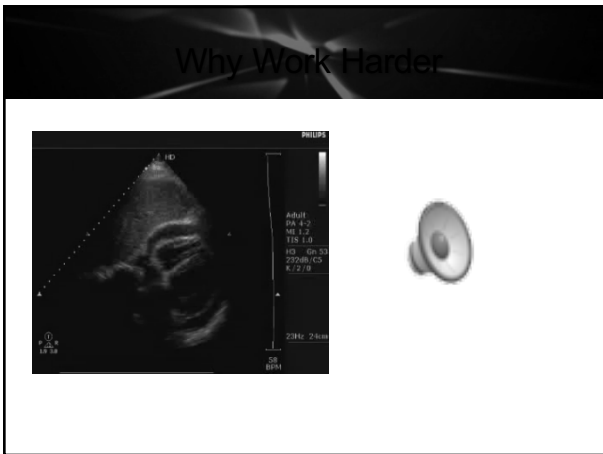


Paramedic Ultrasound









Testimonial


I am not advocating the use of any particular device or company.

At the Trauma Center!

You radio ahead your findings

Increase the IVF's
Start Pressors

Maybe you even have the option to do a field pericardiocentesis?



The Data

- **Use of prehospital ultrasound in North America: a survey of emergency medical services medical directors**
 - John Taylor^{1,2}, Kyle McLaughlin², Andrew McRae², Eddy Lang² and Andrew Anton²
 - Of respondents, 4.1% of EMS systems (95% CI 1.9, 6.3) reported currently using ultrasound
 - and an additional 21.7% (95% CI 17, 26.4) are considering implementing ultrasound.
 - The most commonly cited current and projected applications are Focused Abdominal Sonography for Trauma (FAST) and assessment of pulseless electrical activity (PEA) arrest.
 - The cost of equipment and training are the most significant barriers to implementation of ultrasound.
 - Most medical directors want evidence that prehospital ultrasound improves patient outcomes prior to implementation.

BMC Emergency Medicine 2014, **14**:6 doi:10.1186/1471-227X-14-6

EMS Technology

- Monitoring devices
- Diagnostic 12 lead EKGs
- Continuous ETCO2 capnography
- I-Stat lab value testing
- I/O
- CPAP

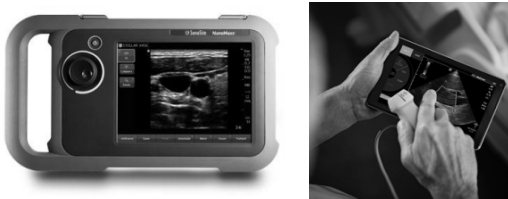- We have never been able to do diagnostic imaging or peer into the body to get a real time look as to what was going on!

It's Too Expensive!

- Although once it was common place for Ultrasound devices to cost in excess of \$70,000, there are many entry level devices in the \$8,000-\$16,000 range.



Camel Fire Department



It's Too Hard to Learn!

ULTRASOUND DETECTION OF PNEUMOTHORAX WITH MINIMALLY TRAINED SONOGRAPHERS: A PRELIMINARY STUDY

Jonathan D. Monti, MPAS, PA-C; Bradley Younggren, MD, FACEP; Robert Blankenship, MD, FACEP

Department of Emergency Medicine / Charles A. Andersen Simulation Center, Madigan Army Medical Center, Ft Lewis, WA

KEYWORDS
ultrasound, pneumothorax, military

ABSTRACT
Background: Prompt recognition and treatment of a tension pneumothorax is critical to reducing mortality in both military and civilian settings. Physician assistants, Special Operations Forces (SOF) and conventional force Medics are often the first medical providers to care for combat trauma patients with penetrating chest trauma and frequently have limited diagnostic capabilities available to them due to mission constraints. The purpose of this study is to examine the potential for non-physician providers to determine the absence or presence of a pneumothorax in a

Prehospital Ultrasound by Paramedics: Results of Field Trial

- **Authors:** Heegaard, William Hidebrand, David; Speer, David Chason, Kevin Nelson Bret, Ho, Jeffrey
- **Source:** Academic Emergency Medicine Volume 17, Number 6, June 2010, pp.624-630(7)
- **Publisher:** Wiley-Blackwell

- 104 patients with prehospital ultrasound
 - Aortic Aneurysm
 - FAST exam for free fluid, pericardial fluid
 - Paramedics had a 100% agreement with PO
 - Inadequate images in less than 8%
- I have no doubt in my mind that paramedics can become as good as any other provider in performing and interpreting limited ultrasound applications!

Applications

- Diagnostic vs. Therapeutic
 - FAST (or pFAST)
 - Lung Sliding (for pneumothorax)
 - TRUE (tracheal intubation)
 - FEEL (cardiac medical)
 - AAA
 - Volume Status
 - Pregnancy
 - PIV Placement

FAST

- In EMS systems with regionalized trauma care and field triage guidelines earlier detection of pericardial effusions in patients with penetrating thoracic trauma or of intra-abdominal free fluid in patients with blunt trauma can be very helpful in helping providers decide on the method of transport and trauma center level destination.


FAST

Liver Laceration

The Data

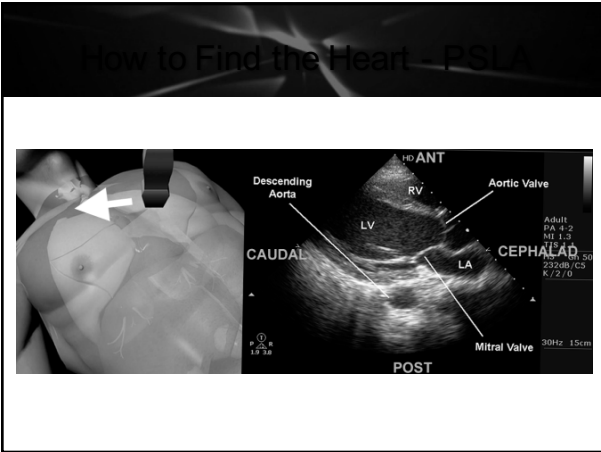
- In one prospective multicenter study of 202 trauma patients
 - pFAST 93%, 99%, and 99%, resp., compared with 93%, 52%, and 57% for Physical Exam.
 - The PFAST examination time had a mean of 2-4min (SD 0-8)
 - Was completed 35min prior to a regular emergency department exam.
 - A change in prehospital management, mainly fluid resuscitation, was reported in up to 21% of patients when PFAST was used.
 - PFAST findings also influenced the decision making process regarding the mode of transport (ground versus helicopter) and the choice of hospital destination in up to one-third of patients.

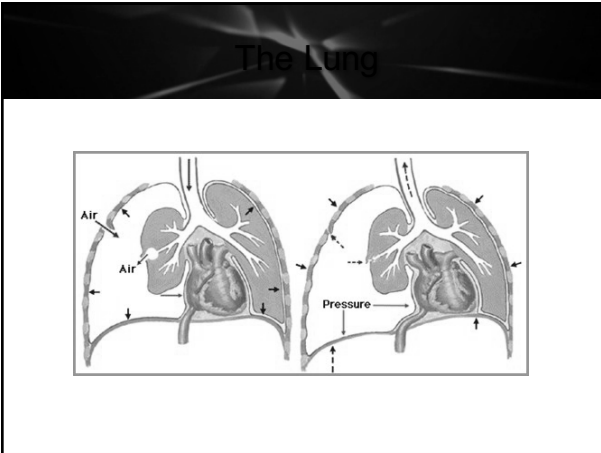
Sub-Xiphoid View



The Up Side of FAST







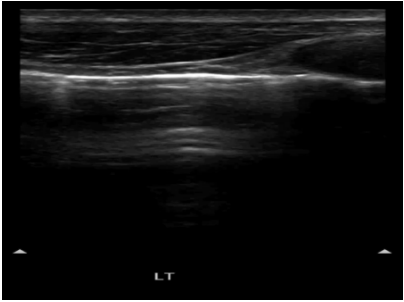
Lung Sliding

- How many of you have ever done a chest needle decompression?
- How many of your patients actually had a pneumothorax?
- Wouldn't it be great to know who had a collapsed lung before you gave them one with your BFN?


Lung Sliding

- Ultrasound detection of the sliding lung sign by prehospital providers
 - American Journal of Emergency Medicine (2012) 30, 485–488
 - Sensitivity and Specificity of 100%
- Ultrasound detection of PTX?
 - Several studies comparing CXR to US to detect PTX
 - 95% sensitive, 91% specific, NPV of 100%
 - U/S did BETTER than AP CXR

Lung Sliding



Comet Tailing



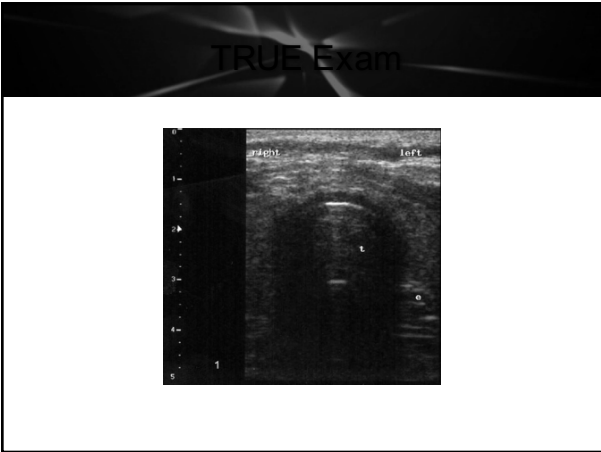


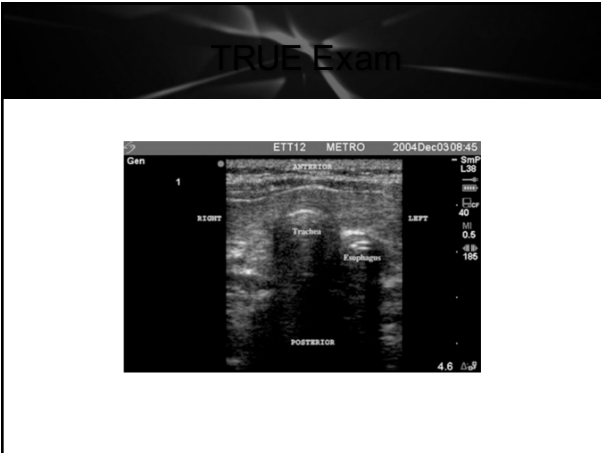Endotracheal Tube Verification

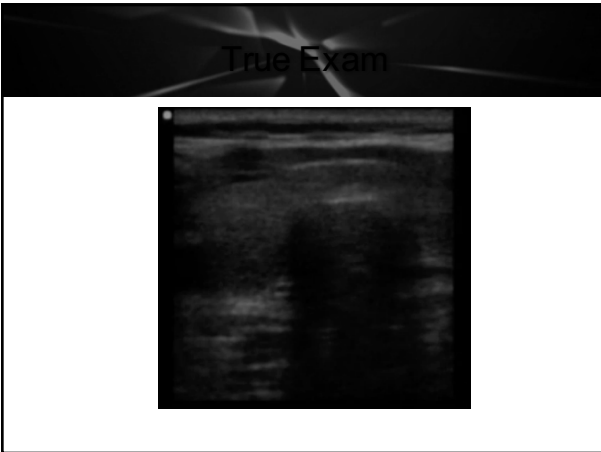
- What are our current options?
 - Visualization
 - Misting in the rube
 - Colormetric ETCO2
 - Continuous Waveform
 - EDD ?
- What about Ultrasound?

Critical Care Ultrasound Journal

- Crit Ultrasound J. 2013 Jul 4;5(1):7
- Study looked at 107 patients
- US
 - Accuracy - 98.1 %
 - Sensitivity - 98%
 - PPV - 98%
 - NPV - 100%
- Time to perform US - 16.4 sec
- Concluded US can replace waveform capnography to confirm ETT placement









Cardiac Arrest

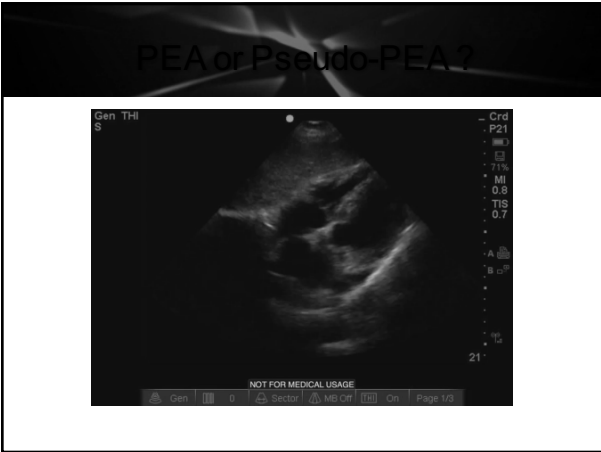- **Resuscitation**, 2010 Nov;81(11):1527-33. doi: 10.1016/j.resuscitation.2010.07.013.
- **Focused echocardiographic evaluation in life support and peri-resuscitation of emergency patients: a prospective trial.**
 - A total of 230 patients were included
 - 204 undergoing a FEEL examination during
 - ongoing cardiac arrest(100)
 - and in a shock state (104).
 - Images of diagnostic quality were obtained in 96%.
 - In 35% of those with an ECG diagnosis of asystole,
 - and 58% of those with PEA,
 - coordinated cardiac motion was detected, and associated with increased survival. Echocardiographic findings altered management in 78% of cases.

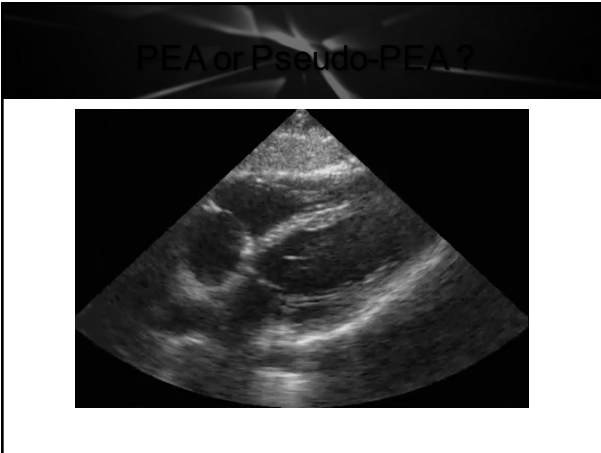
Cardiac Arrest



PEA or Pseudo-PEA?







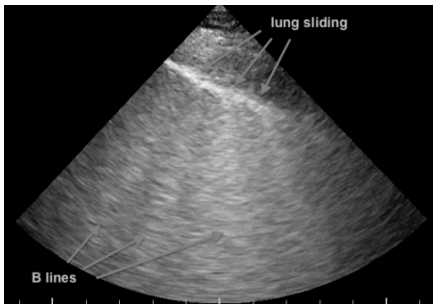
Cardiac Arrest

- [Am J Emerg Med](#). 2005 Jul;23(4):459-62.
- **Does the presence or absence of sonographically identified cardiac activity predict resuscitation outcomes of cardiac arrest patients?**
 - Of 70 enrolled subjects, 36 were in asystole and 34 in PEA. Patients presenting without evidence of cardiac kinetic activity did not have return of spontaneous circulation (ROSC) regardless of their cardiac rhythm, asystole, or PEA.
 - Of the 34 subjects presenting with PEA,
 - 11 had sonographic evidence of cardiac kinetic activity,
 - 8 had ROSC with subsequent admission to the hospital, and
 - 1 had survived to hospital discharge with scores of 1 on the Glasgow-Pittsburgh Cerebral Performance scale and 1 in the Overall Performance category.

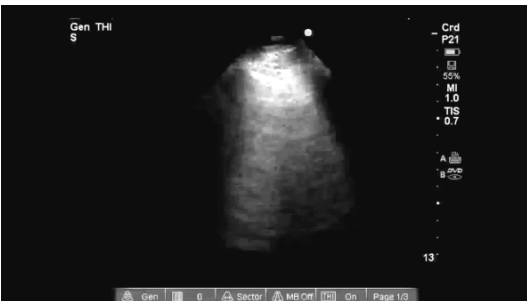CHF or COPD?

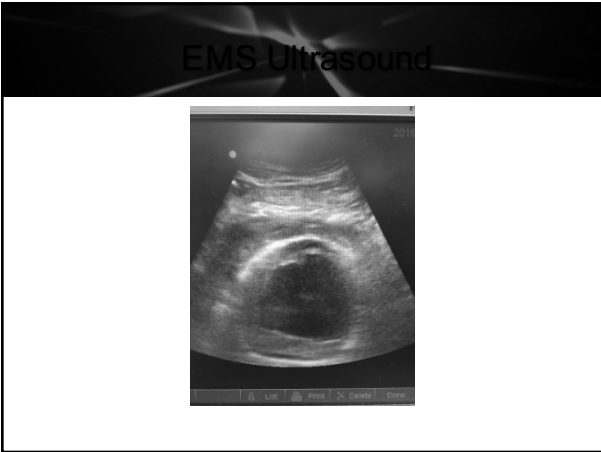- Prehospital ultrasound improves the accuracy of diagnosing pulmonary edema as the cause of acute dyspnea.
 - In a prospective cohort study of 218 patients presenting with acute dyspnea (heart failure or COPD/asthma related), ultrasound performed in less than one minute, was found to be the strongest predictor for the diagnosis of heart failure in the prehospital setting.
 - Ultrasound was superior to both point-of-care N-terminal probrain natriuretic peptide testing and to clinical examination using Boston modified criteria
 - Seeing B-lines (sonographic artifacts caused by the interaction of water-rich structures and air) on the initial lung ultrasound had 100% sensitivity, 95% specificity, 100% negative predictive value, and 96% positive predictive value for the diagnosis of heart failure in the prehospital setting [17, 19].

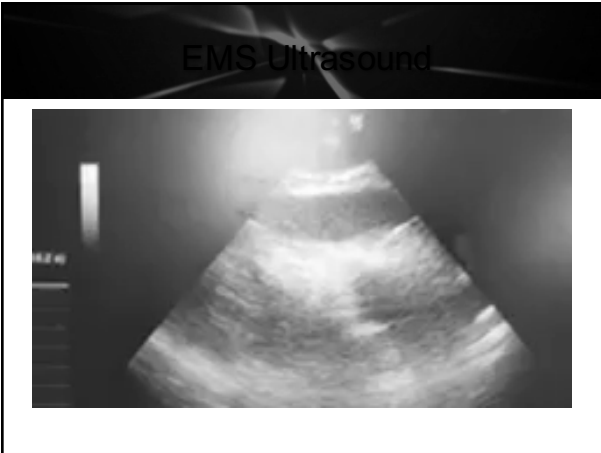
B-lines



B-lines







Summary

- Ultrasound is here to stay and is rapidly becoming a diagnostic tool for all level of healthcare provider.
- Price-point for various devices has allowed this technology to be adopted in the prehospital setting.
- Outcome data is rapidly validating its use by EMS professionals
- Training on various applications can easily be done in 4-6 hours focused sessions.

Questions?

- Any questions?

Beneficial Uses to EMS

- TRUE – Verification of ETTI
- Thoracic – PTX and CHF
- Cardiac – PEA vs. Pseudo-PEA, Tamponade
- FAST – Abdominal Trauma

- Abdomen – AAA
- PIV Placement
- Hydration status
- Community Paramedic Uses

References

- **Paramedic Ultrasound** - Don't object unless you have all of the facts! by [Peter Bonadonna](#), EMT-P, CIICC, [Monroe Community College Paramedic Program](#)
- Ultrasound Applications in EMS, Jason Bowman, MS, LP, CCEMT-P | From the September 2010 Issue | Wednesday, September 1, 2010
- **Prehospital Emergency Ultrasound: A Review of Current Clinical Applications, Challenges, and Future Implication:** [Mazen J. El-Sayed](#) and [Elie Zaghrini](#)
- EMS and US Where/Is it Useful, R. Blankenship, MD, FACEP, Chairman, St. Vincent Fishers Emergency Department

- Questions?
- makaufmann@me.com
